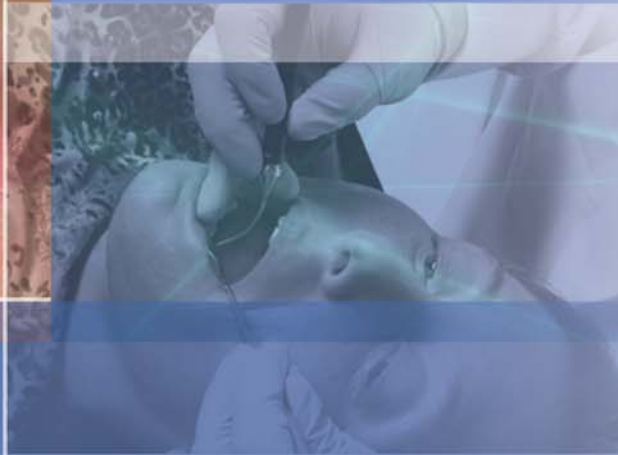
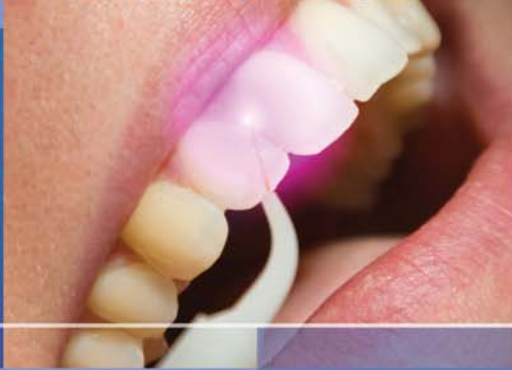
Introduction



to the Laser-assisted New Attachment Procedure for the Treatment of Periodontitis

by Robert H. Gregg II, DDS

The breakthrough Laser-assisted New Attachment Procedure (LANAP) offers many advantages over conventional flap periodontal surgery or scaling and root planing for the treatment of periodontitis. This no-cut, no-sew technique is bringing revolutionary outcomes into the treatment rooms of general dentists and periodontists alike, allowing the profession to battle against a disease that threatens the health of more than 80 percent of Americans. This overview explains what the Laser-assisted New Attachment Procedure (LANAP) is, how it works and what clinical trials are showing about the exciting results this strict protocol can achieve for patients with gingivitis, “garden variety” peri-

odontitis, and even the most extremely severe forms of gum disease.

After reading this article, the reader should be able to:

- appreciate the proportion of American patients who suffer from moderate to severe gum disease.
- summarize the steps and components of the LANAP protocol for treating periodontitis.
- understand the differences between conventional flap surgery and laser-assisted new attachment procedures.
- have an awareness of the percentage of general practitioners who perform probe examinations and the need for more.

Dentaltown is pleased to offer you continuing education. You can read the following CE article, take the post-test and claim your **two AGD PACE** continuing education credits. See instructions on page 113.



Approved PACE Program Provider
FAGD/MAGD Credit
Approval does not imply acceptance
by a state or provincial board of
dentistry or AGD endorsement.
12/01/2004 to 12/31/2012

Most Americans – about 80 percent – suffer with gum disease on some level, according to the U.S. Surgeon General. Michael Newman, DDS, PhD, says that only three percent of the 100 million-plus Americans with moderate to severe periodontal disease are treated each year, which means an increasing number of worsening cases appear in general dental practices across the country every day. The growing threat requires a greater number of general dentists to take the lead in properly performing a periodontal probing exam. Still, for many offices, the challenge lies in persuading the patient to seek treatment via referral to a periodontist.

A growing number of general practitioners have reached a frustration threshold, seeing one patient after another who either continues with poor gum health or seeks treatment from a periodontist and achieves results that ultimately leave much to be desired. Some of these dentists have discovered a treatment protocol that allows them to take action and provide patients with improved care, without even referring them out of the practice. The treatment is achieving unsurpassed results not otherwise attainable with conventional techniques.

Widely known to be closely linked with heart disease and strokes, periodontitis has now been fingered as the cause in a full-term baby's death.² It is believed that the mother's gum disease introduced fatal bacteria to her womb. In an age of burgeoning technology, the news stories linking gum disease to more disastrous results are inevitable. As the dangerous consequences of gum disease become increasingly clear, more dental clinicians must take the reins in educating patients and ensuring their successful treatment.

Dental practitioners have used free-running (FR) pulsed Nd:YAG lasers for more than 20 years, but only recently has the laser been combined with a specific, successful protocol and research-proven operating parameters to achieve FDA clearance and a track record of success in

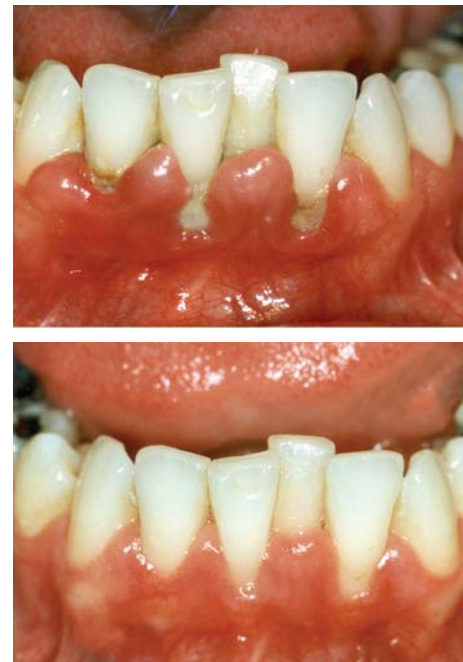university-based clinical studies for its efficacy at “cementum-mediated new PDL attachment to the tooth root surface in the absence of long junctional epithelium.”^{3,4} The protocol has shown consistent probe depth reduction, histological and clinical new attachment and radiographic bone growth for periodontally involved teeth with no elevation of the periosteum and minimal patient discomfort.⁵⁻⁷

Its greatest potential may lie in patients' willingness to accept treatment and comply. With 97 percent refusing current protocols, a no-cut, no-sew solution has meant a flock of new patients willing to seek treatment for their gum disease from those dentists who choose to offer the LANAP protocol.

What is the LANAP Protocol?

The procedure combines the PerioLase MVP-7 free-running (FR) pulsed Nd:YAG laser with a strict, specific, research-proven protocol that has achieved FDA clearance for the treatment of all forms of gum disease – from early detection to so-called “hopeless” teeth. The breakthrough is called Laser-assisted New Attachment Procedure, and it has left a trail of healthy patients in its wake for the inventors of the protocol, Drs. Robert H. Gregg II and Delwin K. McCarthy, as well as more than a thousand dentists and specialists who have learned the procedure from the Institute for Advanced Laser Dentistry (IALD).

Drs. Gregg and McCarthy pioneered the use of the FR pulsed Nd:YAG laser in treating gum disease in the 1990s. They were astounded by their ability to regenerate bone growth (routine 50 percent defect fill) and stimulate new attachment for their own patients with severe gum disease. The results were too good to keep to themselves.



Top: Before
Bottom: Nine days after LANAP

1. Faculty Bio pages. UCLA School of Dentistry Web site. Michael G. Newman, BA, DDS, FACP, <http://www.dent.ucla.edu/bio/bio.asp?id=277>. Accessed on March 13, 2008.
2. Carroll, Linda. Mother's gum disease linked to infant's death. <http://www.msnbc.msn.com/id/34979552/>. Accessed February 25, 2010.
3. Myers TD, Myers WD, Stone RM. First soft tissue study utilizing a pulsed Nd:YAG dental laser. *Northwest Dent*. 1989;68: 14-17.
4. White JM, Goodis HE, Rose CL. Use of the pulsed Nd:YAG laser for intraoral soft tissue surgery. *Lasers Surg Med*. 1991;11:455-461.
5. Gregg RH II, McCarthy D. Laser periodontal therapy: case reports. *Dent Today*. Oct 2001;20:74-81.
6. Gregg RH II, McCarthy D. Laser periodontal therapy for bone regeneration. *Dent Today*. May 2002;21:54-59.
7. 501(k)s final decisions rendered for July 2004 (PerioLase MPV-7, 510(k) number K030290). US FDA Center for Devices and radiological Health Web site. <http://www.fda.gov/cdrh/510k/sumjul04.html>. Updated August 9, 2004. Accessed January 2, 2008.

The pair continued to fine-tune the procedure after patenting it so that they could share it with their peers and set a goal for the new gold standard for the treatment of gum disease across the country.

Designed and refined over 10 years, **the LANAP technique's specific clinical steps must be performed properly and in precise order to achieve consistent positive outcomes.** The key steps, in order, make up the patented portion of the technique and are the crux of why the LANAP protocol is so successful. The procedure may be performed in all four quadrants in a single appointment, but for patient comfort and case control, laser treatment is typically limited to no more than two non-adjacent quadrants per visit, with several days between visits.

First, the patient is profoundly anesthetized with local anesthetic so that the patient's pocket depths can be probed down to the level of intra-osseous defects (bone sounding). The thin optic fiber is then used parallel to the root surface, to affect the pocket wall. Next, an EMS ultrasonic scaler removes calcified plaque and calculus adherent to the root surface. The first pass with the laser, called laser troughing, is accomplished with the short duration pulse. The FR pulsed Nd:YAG laser is used to achieve optimal reduction of microbial pathogens (antiseptis) within the periodontal sulcus and surrounding tissues. Perio pathogens and pathologic proteins are selectively destroyed by the laser's light energy, providing an antiseptic surgical environment that allows healing following the laser hemostasis step.⁸⁻¹⁵

The technique uses selective photothermolysis to remove the diseased, infected and inflamed

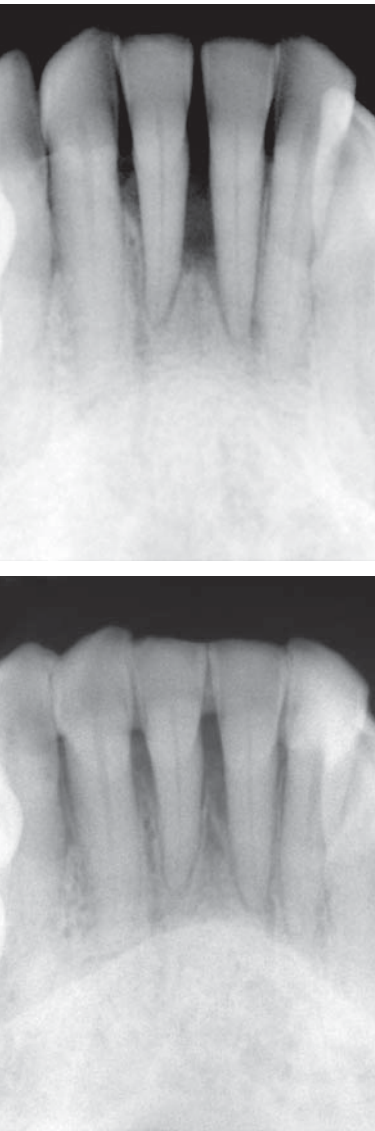
pocket epithelium while preserving healthy connective tissue, literally separating the tissue layers at the level of the rete pegs and ridges.⁸⁻¹¹ The practitioner is able to achieve both tissue ablation and antiseptic hemostasis with extreme precision by varying the laser's energy density, pulse duration and rate of repetition. The laser assists in the destruction of perio pathogens while preserving the healthy tissue, allowing for less post-operative discomfort and a much shorter post-surgical recovery perception for the patient.

At this point, a second pass is completed to finish debriding the pocket and achieve hemostasis with a thermal fibrin clot. Gingival tissue is compressed against the root surface as necessary to close the pocket and aid with formation and stabilization of the fibrin clot. No sutures or surgical glue is needed. Mobile teeth above Class II mobility are splinted. Occlusal adjustments are performed to remove interferences, minimize trauma and provide balance to long axis forces and are considered an essential component of the LANAP protocol.

Finally, post-operative instructions specific to the LANAP protocol, diet guidelines and oral hygiene instructions are explained and their importance is stressed, and continued periodontal maintenance is scheduled. Patients are monitored at one week, 30 days and then every three months for periodontal maintenance. No subsequent probing is performed for at least six months to a year to allow sufficient healing time for the cementum-fiber PDL interface.

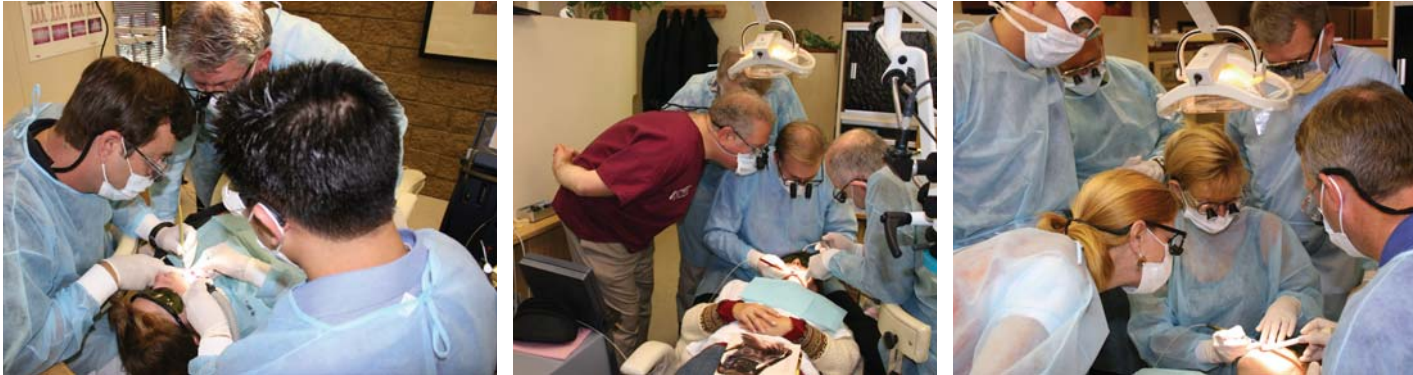Harnessing the LANAP Protocol's Results

The availability of a procedure that eliminates cutting and sewing without gum recession is changing the standard of care for periodontitis treatment. Not only is there a treatment protocol that is universally accepted by patients, but it also



Top: Pre-LANAP
Bottom: Post-LANAP

8. Yukna RA, Evans GH, Vastardis S, et al. Human periodontal regeneration following the laser assisted new attachment procedure. Paper presented at: IADR/AADR/CADR 82nd General Session; March 10-13, 2004; Honolulu, HI. Abstract 2411. http://iadr.confex.com/iadr/2004Hawaii/techprogram/abstract_47642.htm. Accessed January 2, 2008.
9. Neill ME, Mellonig JT. Clinical efficacy of the Nd:YAG laser for combination periodontitis therapy. *Pract Periodontics Aesthet Dent.* 1997;9(suppl):1-5.
10. Gregg RH, McCarthy DK. Laser ENAP for periodontal ligament regeneration. *Dent Today.* 1998;17:86-89.
11. Gregg RH, McCarthy DK. Laser ENAP for periodontal bone regeneration. *Dent Today.* 1998;17:88-91.
12. Middel M, Renton-Harper P. Lasers in dentistry. *Br Dent J.* 1991;170:343-346.
13. Moritz A, Schoop U, Goharkhay K, et al. The bactericidal effect of Nd:YAG, Ho:YAG, and Er:YAG laser irradiation in the root canal: an in vitro comparison. *J Clin Laser Med Surg.* 1999;17:161-164.
14. Whitters CJ, Macfarlane TW, MacKenzie D, et al. The bactericidal activity of pulsed Nd:YAG laser radiation in vitro. *Lasers Med Sci.* 1994;9:297-303.
15. Harris DM. Ablation of *Porphyromonas gingivalis* in vitro with pulsed dental lasers. Paper presented at: 32nd Annual Meeting and Exhibition of the AADR; March 12-15, 2003; San Antonio, TX. Abstract 855. http://iadr.confex.com/iadr/2003SanAnton/techprogram/abstract_27983.htm. Accessed January 2, 2008.



Live patient clinical hands-on training with direct instructor supervision

represents an option that includes both specialists and general practitioners in the solution. A general practitioner who might be reluctant to perform invasive surgery might welcome the opportunity to treat such an overwhelming health issue without referring patients elsewhere. Alternatively, the LANAP protocol practiced by periodontal specialists becomes a more attractive referral for general practitioners and their patients.

Those who choose to embrace the LANAP protocol do so with an extensive support system in place. Clinicians are required to undergo extensive training and adhere to the protocols that have proven successful before performing the LANAP technique. Millennium Dental Technologies, the manufacturer of the PerioLase MVP-7, requires that clinicians first satisfactorily complete a three-day lecture course and live, hands-on patient treatment and patient response before the company will even ship the laser and all the essential elements of the protocol. Additional study follows the initial training.

The Science Behind the LANAP Protocol

Early LANAP protocol research showed consistent mean pocket depth reduction (nearly 50 percent) and improved bone density (38 percent) in an eight-year retrospective study of the protocol's earliest clinical results. The Emago imaging system demonstrated that 100 percent of these cases showed bone density increases. The procedure has also proven effective at reducing pocket depth without gingival recession over a six-month period.^{16,17}

In the fourth-largest human histological study in the perio regeneration literature (with a control group), the LANAP protocol using the PerioLase MPV-7 was compared to a blinded examiner (clinical) conventional scaling and root planing without laser assistance. Twelve teeth were removed *en bloc* and examined by a blinded histologist. When the blinded code was broken, all teeth treated with the LANAP protocol demonstrated 100 percent cementum-mediated new periodontal ligament attachment to the previously periodontally affected tooth roots in all six of the LANAP-treated teeth and in the absence of long junctional epithelium.⁸⁻¹¹ These results are unique in the perio literature.

Given its unique, predictably regenerative results, it should come as no surprise that the LANAP protocol has inspired its share of imitators. As yet, those copycat protocols have no science to support their continued use. The patented LANAP protocol is the only peer-reviewed and FDA-cleared approach that is proven successful at treating mild, moderate and especially severe periodontitis.

LANAP Protocol vs. Cut-and-Sew Procedures

The successful treatment of periodontal disease requires thorough debridement of the root surface. Pockets of 5mm or greater depth make it difficult to remove subgingival plaque and calculus. Surgical intervention allows access and visualization for scaling and root planing in these deep pockets.¹⁸ While scalpel surgery can accomplish such access and visualization, it can also result in

16. Harris DM. Dosimetry for laser sulcular debridement. *Laser Surg Med.* 2003;33:217-218.

17. Harris DM, Gregg RH II, McCarthy DK, et al. Laser-assisted new attachment procedure in private practice. *Gen Dent.* 2004;52:396-403.

16. Harris DM. Dosimetry for laser sulcular debridement. *Laser Surg Med.* 2003;33:217-218.

attachment loss, gingival cratering and gingival recession.¹⁹⁻²² Additionally, the associated pain and discomfort can be deterrents.²³ In any case, many general practitioners would never consider performing conventional flap surgery because of its invasive nature.

LANAP treatment, while an exceptional alternative, is not without its drawbacks. The predominant issues involve cost and time. The initial financial outlay for the laser equipment can be cost-prohibitive for some practices. Similarly, dental clinicians must be willing and able to **take time away from the office to undergo procedural training and learn LANAP treatment with live patients.** Following the training, and as with anything new, there can be a learning curve as clinicians grow comfortable and begin to excel at treating patients with LANAP.

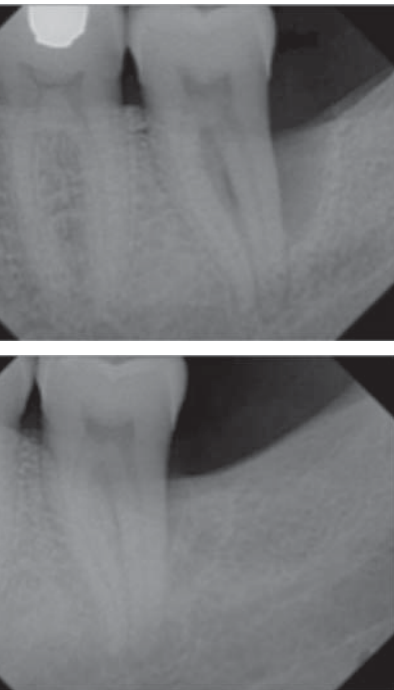
For now, cut-and-sew techniques remain the standard of care and additional study will be required to persuade many professionals that any laser system provides clinical value surpassing scaling and root planing techniques and conventional surgical treatment.²⁴ Cautious experts warn that the improper use of the Nd:YAG laser can have detrimental effects on the root surface ranging from heat cracking to charring, cementum meltdown and crater forma-

tion.²⁵ **These negative outcomes are not typical with adherence to current LANAP protocols and thus appear to result from improper laser settings.** Studies continue, and most researchers agree that laser or laser-assisted pocket therapy is expected to become a new technical modality in periodontics.²⁶

The LANAP treatment protocol achieves the same access to the problem that root planing and scaling or conventional flap surgery does, but it achieves its success differently. The practitioner uses a quartz fiber in place of a scalpel to achieve both tissue ablation and antibiotic properties. No cutting means a significantly more comfortable recovery. Patients typically remain on a soft diet for several days to a week following LANAP treatment and are instructed to avoid brushing at the surgical site for that period.

Conclusion

Whereas treatment outcomes with conventional modalities might be variable; in stark contrast, the LANAP protocol allows clinicians to achieve predictable, positive results – including the three-dimensional regeneration of bone. Also, the comfort levels associated with this minimally invasive treatment are substantially increasing patient acceptance rates. Ongoing additional studies are expected to underscore the LANAP protocol advantages and pave the way for its acceptance as a standard of care in treating patients with moderate to severe gum disease. ■



Top: Pre-LANAP, April 2009
Bottom: Post-LANAP, May 2010

19. Becker W, Becker BE, Ochslein C, Kerry G, Caffesse R, Morrison EC, Prichard J. A longitudinal study comparing scaling, osseous surgery, and modified Widman procedures. Results after one year. *J Periodontol* 1988;59:351-365.
20. Pihlstrom BL, Ortiz-Campos C, McHugh RB. A randomized four-years study of periodontal therapy. *J Periodontol* 1981;52:227-242.
21. Kaldahl WB, Kalkwarf KL, Patil KD, Dyer JK, Bates RE Jr. Evaluation of four modalities of periodontal therapy. Mean probing depth, probing attachment level, and recession changes. *J Periodontol* 1988;59:783-793.
22. Hill RW, Ramsford SP, Morrison EC, Appleberry EA, Caffesse RG, Kerry GJ, Nisile RR. Four types of periodontal treatment compared over two years. *J Periodontol* 1981;52:655-662.
23. Curtis JW Jr, McLain JB, Hutchinson RA. The incidence and severity of complications and pain following periodontal surgery. *J Periodontol* 1985;56:597-601.
24. Matthews, Debra C. The truth about soft tissue lasers and nonsurgical periodontal therapy. *JCDA* 2010.
25. Chanthaboury, Rachel, Irinakis, Tassos. The use of lasers for periodontal debridement: marketing tool or proven therapy? *JCDA* Oct 2005.
26. Ishikawa, Isao; Aoki, Akira; Takasaki, Aristeo A.; Mizutani, Koji; Sasaki, Katia M; Izumi, Yuichi. *Periodontology* 2000 May 2009.

Author's Bio

Dr. Robert Gregg is a former faculty member at UCLA School of Dentistry. He has been using lasers clinically since August 1990, including CO₂, free-running pulsed (FRP) Nd:YAG, both single and variable pulsed; FRP Ho:YAG, surgical Argon, CW diodes and Er:YAG. He has given lectures nationally and internationally on the subject of clinical laser applications, and has conducted seminars for the UCLA Department of Continuing Education. Dr. Gregg, along with Delwin K. McCarthy, DDS, formed The Institute for Advanced Laser Dentistry (IALD) in 2001.



Post-test

Claim Your CE Credits

Answer the test in the Continuing Education Answer Sheet and submit it by mail or fax with a processing fee of \$36. We invite you to view all of our CE courses online by going to <http://www.dentaltown.com/onlinece> and clicking the View All Courses button. Please note: If you are not already registered on www.dentaltown.com, you will be prompted to do so. Registration is fast, easy and of course, free.

- What is “laser troughing”?
 - Debridement of the calculus with the laser
 - The first pass with the laser, accomplished with long pulses
 - The second pass with the laser, accomplished with short pulses
 - The first pass with the laser, accomplished with short pulses
- How many Americans are estimated to have moderate to severe periodontitis?
 - 80 percent
 - More than 100 million
 - Fewer than 80 million
 - 50 percent
- Which of the following is *not* linked to gum disease?
 - Diabetes
 - Fatal pregnancy complications
 - Bleeding gums
 - Heart disease
- Which of the following are drawbacks of conventional flap surgery?
 - Pain and discomfort of recovery
 - Attachment loss
 - Gingival cratering and recession
 - All of the above
- Which of the following was shown about the LANAP protocol in a human histological study?
 - More than half the treated teeth formed new attachments at the gum line
 - 100 percent decrease in bleeding gums
 - 100 percent frequency of cementum-mediated new attachment
 - 100 percent frequency of hemostasis in deep pockets
- Who can perform the LANAP protocol?
 - Certified LANAP practitioners, who may be general dentists or specialists
 - Specially trained dentists and dental hygienists
 - Only periodontists with special advanced coursework
 - Dental laser specialists
- Which of the following is considered an important part of the LANAP procedure?
 - 100 percent antiseptis in 5mm pockets
 - Occlusal adjustments to remove interferences, minimize trauma and provide balance to long axis forces
 - Removal of all subgingival calculus
 - Eradication of healthy tissue
- What is the maximum treatment per visit?
 - All four quadrants may be treated in a single visit
 - Only a single quadrant at a time
 - Two non-adjacent quadrants may be treated
 - No more than two adjacent quadrants may be treated
- What is the recommended treatment per visit, for the sake of patient comfort and case control?
 - All four quadrants may be treated in a single visit
 - Only a single quadrant at a time
 - Two non-adjacent quadrants may be treated
 - No more than two adjacent quadrants may be treated
- Which technology does the LANAP protocol utilize?
 - A CO₂ laser
 - Any laser set to the correct frequency may be used
 - The PerioLase MPV-7 laser (Nd:YAG)
 - Short-pulse lasers

Legal Disclaimer: The CE provider uses reasonable care in selecting and providing content that is accurate. The CE provider, however, does not independently verify the content or materials. The CE provider does not represent that the instructional materials are error-free or that the content or materials are comprehensive. Any opinions expressed in the materials are those of the author of the materials and not the CE provider. Completing one or more continuing education courses does not provide sufficient information to qualify participant as an expert in the field related to the course topic or in any specific technique or procedure. The instructional materials are intended to supplement, but are not a substitute for, the knowledge, expertise, skill and judgment of a trained healthcare professional. You may be contacted by the sponsor of this course.

Licensure: Continuing education credits issued for completion of online CE courses may not apply toward license renewal in all licensing jurisdictions. It is the responsibility of each registrant to verify the CE requirements of his/her licensing or regulatory agency.

Continuing Education Answer Sheet

Instructions: To receive credit, complete the answer sheet and mail it, along with a check or credit card payment of \$36 to: Dentaltown.com, Inc., 9633 S. 48th Street, Suite 200, Phoenix, AZ 85044. You may also fax this form to 480-598-3450. You will need a minimum score of 70 percent to receive your credits. **Please print clearly. Your certificate will be mailed to you within 3-4 weeks.**

Introduction to the Laser-assisted New Attachment Procedure for the Treatment of Periodontitis

by Robert H. Gregg II, DDS

License Number _____

AGD# _____

Name _____

Address _____

City _____ State _____ ZIP _____

Daytime phone _____

E-mail (optional) _____

Check (payable to Dentaltown.com, Inc.)

Credit Card (please complete the information below and sign; we accept Visa, MasterCard and American Express.)

Card Number _____

Expiration Date – Month / Year _____ / _____

Signature _____ Date _____

Yes, I would like to continue receiving *Dentaltown Magazine* free of charge

(Signature required for subscription - free to U.S. only)

No, thank you.

Program Evaluation (required)

Please evaluate this program by circling the corresponding numbers: (3 = Excellent to 1 = Poor)

1. Course objectives were consistent with the course as advertised 3 2 1

2. Course material was up-to-date, well-organized and presented in sufficient depth 3 2 1

3. Instructor demonstrated a comprehensive knowledge of the subject 3 2 1

4. Overall, I would rate this course 3 2 1

5. Overall, I would rate this instructor 3 2 1

For questions, contact Director of Continuing Education Howard Goldstein at hogo@dentaltown.com

CE Post-test

Please circle your answers.

1. a b c d
2. a b c d
3. a b c d
4. a b c d
5. a b c d
6. a b c d
7. a b c d
8. a b c d
9. a b c d
10. a b c d

Field of practice (optional)

- | | |
|---|---|
| <input type="checkbox"/> General Dentist | <input type="checkbox"/> OMS Resident |
| <input type="checkbox"/> Anesthesiology | <input type="checkbox"/> Oral Pathology |
| <input type="checkbox"/> Consultant | <input type="checkbox"/> Orthodontics |
| <input type="checkbox"/> Cosmetic Dentistry | <input type="checkbox"/> Orthodontic Resident |
| <input type="checkbox"/> Dental Assistant | <input type="checkbox"/> Pediatric Dentistry |
| <input type="checkbox"/> Dental Company Rep. | <input type="checkbox"/> Pediatric Resident |
| <input type="checkbox"/> Dental Education | <input type="checkbox"/> Periodontics |
| <input type="checkbox"/> Dental Lab Tech | <input type="checkbox"/> Periodontic Resident |
| <input type="checkbox"/> Dental Student | <input type="checkbox"/> Prosthodontics |
| <input type="checkbox"/> Dental Hygiene Student | <input type="checkbox"/> Public Health |
| <input type="checkbox"/> Endodontics | <input type="checkbox"/> Radiology |
| <input type="checkbox"/> Endodontic Resident | <input type="checkbox"/> Speaker |
| <input type="checkbox"/> Front Office | <input type="checkbox"/> TMD Specialist |
| <input type="checkbox"/> Hygienist | <input type="checkbox"/> Other |
| <input type="checkbox"/> Implantology | |
| <input type="checkbox"/> Oral & Maxillofacial Surgeon | |