

PERIODONTICS

Laser Periodontal Therapy: *Case Reports*



Robert H. Gregg II,
DDS



Delwin McCarthy,
DDS

Laser periodontal therapy (LPT) is a laser-based procedure developed specifically for the treatment of moderate to advanced periodontitis. It was patterned after the excisional new attachment procedure (ENAP)¹ to selectively remove diseased and necrotic tissue within the sulcus, but the laser replaced the scalpel. Originally referred to as Laser-ENAP,^{2,3} LPT has evolved to provide a minimally invasive alternative to flap surgeries. Other advantages of LPT include improved hemostasis intraoperatively and improved patient comfort and acceptance. The procedure combines the best aspects of laser soft tissue surgery with well-established principles of periodontal disease therapy. The cases presented here show that for some patients LPT can provide clinical outcomes comparable with invasive surgical procedures.

The step-by-step surgical technique is outlined in Figure 1. This technique selectively removes sulcular and pocket epithelium, preserving connective fibrous tissues and Reté pegs.⁴ The primary endpoint of LPT is debridement of inflamed and infected connective tissue within the periodontal sulcus and removal of calcified plaque and calculus adherent to the root surface. In addition, the bacteriocidal effects of the free-running pulsed Nd:YAG laser plus intraoperative use of topical antibiotics are intended for the reduction of microbiotic pathogens (antiseptics) within the periodontal sulcus and surrounding tissues.⁵⁻⁷ The wound is stabilized and occlusal trauma minimized to promote healing. Oral

hygiene is stressed and continued periodontal maintenance is scheduled.

The desired result is achieving new attachment of gingival tissue to the root surface, thereby decreasing pocket depth. Ideally, remineralization and regeneration of supporting bone and regrowth of the periodontal ligament will also occur.

The following four cases were selected from our current database of patients with complete probe depth and radiographic follow-up data. They were selected to represent typical results (case Nos. 1 and 2), excellent results (case No. 3), and a problem case (case No. 4).

CASE NO. 1

A 56-year-old white male presented July 23, 1996, with concerns regarding deep pockets, and additional extractions and gum surgery. The patient was referred by an existing patient of record, and was under the care of a local periodontist. Medical history was unremarkable, except for a history of smoking one pack per day.

Oral hygiene was fair with mild tobacco stain; the upper right and lower right quadrants were missing teeth, with multiple crowns throughout and several areas of malocclusion. The condition of the gingiva was typical of a moderate smoker: tissues were pink and fibrous because of constant exposure to heat and nicotine. Radiographs revealed moderate to severe horizontal and vertical bony defects throughout. Periodontal charting around 25 teeth

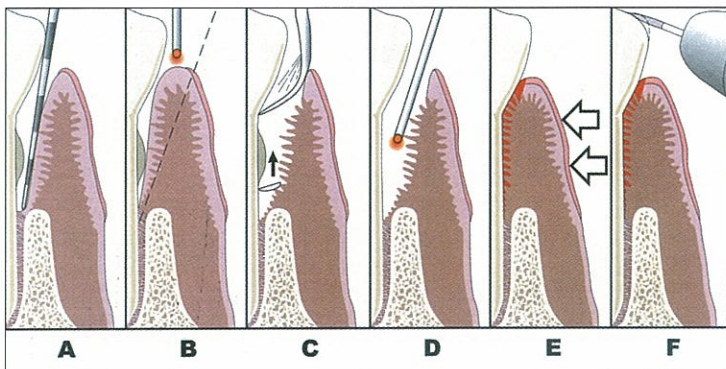
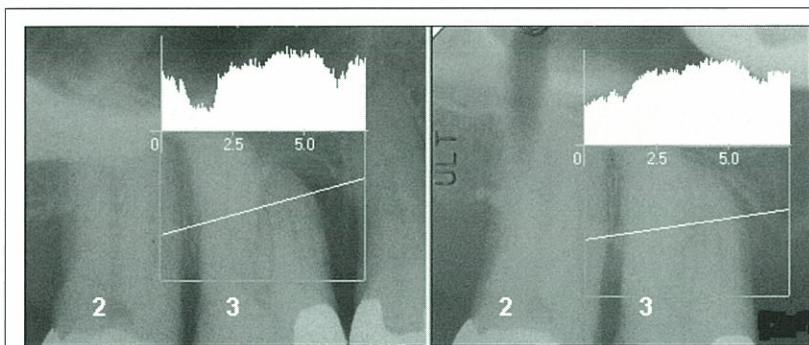


Figure 1. Laser periodontal therapy, step-by-step technique. (A) Periodontal probing indicates excessive pocket depth. (B) Laser troughing: free running pulsed Nd:YAG laser irradiation, at 100 to 150 microseconds pulse duration. Beginning at the gingival crest (not into the sulcus at first). Troughing provides visualization of and access to the root surface by removing necrotic debris, releasing tension, and controlling bleeding. It further defines tissue margins preceding ultrasonic and mechanical instrumentation, preserves the integrity of the mucosa, and aids maintenance of the gingival crest. (C) A piezo-electric scaler, small curettes, and root files are used to remove root surface accretions. (D) A second pass with the Laser at 550 to 650 microseconds pulse duration finishes debriding the pocket, provides hemostasis, and creates a "soft clot." (E) The tissue is compressed against the root surface to close the pocket and stabilize the fibrin clot. (F) Occlusal trauma is adjusted with a high-speed hand-piece, and mobile teeth are splinted.



Pre-Tx		20 Months Post-Tx	
2	3	2	3
6	5	6	3
7	9	6	3
		4	11

Figure 2. Case 1. Left: Radiograph showing close-up of tooth No. 3 before treatment (left) and 20 months post-treatment. Teeth were aligned and gray scales balanced using Emago software. The straight line drawn across the images indicates the location of the radiographic

density profiles (inset). Right: Enlarged view of the mesial 9- to 11-mm pocket (left) and its appearance 20 months post-treatment. Bottom right: Probing depths for teeth Nos. 2 and 3 prior to treatment and at the 20-month follow-up exam.

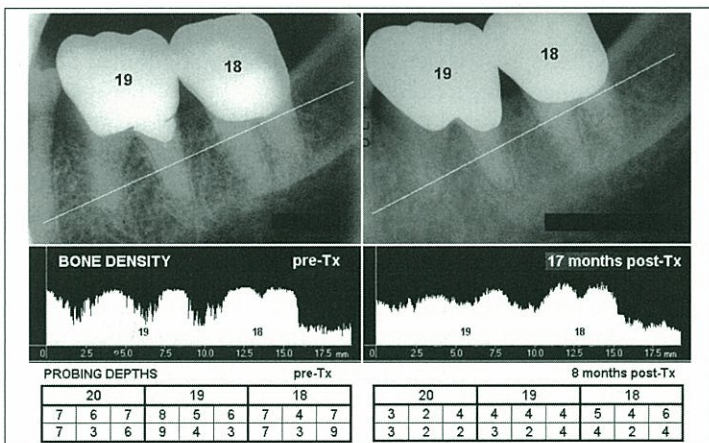


Figure 3. Case 2. Top: Radiograph showing close-up of teeth Nos. 18 and 19 before treatment (left) and 17 months post-treatment. Teeth were aligned and gray scales balanced using Emago software. The straight line drawn across the images indicates the location of the radiographic density profiles. Middle: Density profiles of line drawn on images. Bottom: Probing depths for teeth Nos. 20, 19, and 18 prior to treatment and at the 8-month follow-up exam.

(134 sites) demonstrated generalized moderate to deep pockets up to 11 mm deep. Fifty-three sites were probed \geq 4 mm and 7 sites were probed \geq 8 mm. Mean probe depth (MPD) at baseline was 4.28 mm. The 11-mm defect was located on the mesial-lingual aspect of tooth No. 3 (Figure 2). The patient was confirmed with a diagnosis of generalized moderate to advanced periodontitis and was scheduled for LPT.

One quadrant was treated per visit by the patient's preference. At that time the dLase 300, pulsed Nd:YAG Dental Laser (American Dental Technologies, Inc) was used. In this system there was only one pulse width avail-

able: the 150-microsecond cutting or "short pulse." Troughing around each tooth was done at 150 mJ, 20 Hz (3 watts at the console with 3.4 watts measured at the fiber tip). This laser did not have the capability of recording the total energy delivered, so the actual dosimetry is not available. All quadrants were treated identically except that periodontal dressing was placed on the lower right quadrant. The patient tolerated the procedure well, with no complications or adverse effects (Figure 2).

The patient was evaluated 1 week following treatment of each quadrant. Soft tissue healing was fair, with mild

redness and inflammation. The patient reported that he was having a problem stopping his smoking. Beginning 6 months after the initial treatment, the patient was compliant with 3-month periodontal maintenance follow-ups over the following 2 years.

Mean probe depth changes (MPDCs) are computed by finding the mean of the differences in probing depths from baseline to follow-up. MPDCs at 20 months post-treatment are shown in the first column of the Table (case No. 1). Notice that the seven pockets \geq 8 mm have been reduced by 4.1 mm, from an average of 10.6 mm pretreatment to an average of

6.4 mm at 20 months. Overall pockets ≥ 4 mm (81 sites or 61% of all sites) have been reduced by an average of 1.6 mm. However, the post-op evaluation demonstrated 7-mm pockets remaining on the mesial of tooth No. 3 (pretreatment: 11 mm). Therefore, in July, 1998, tooth No. 3 was retreated.

A comparison of the pre-treatment x-ray of the bone surrounding tooth No. 3 with the x-ray obtained 25 months post-treatment shows strong evidence of bone fill mesially and distally (Figure 2). The density profiles* inset in Figure 2 demonstrate elimination of radiographic evidence of the mesial bony defect and a marked increase in radiographic density interproximal to teeth Nos. 2 and 3.

CASE NO. 2

A 50-year-old white female presented on December 5, 1997, with a history of two previous periodontal subtraction surgeries, and a treatment plan with her present periodontist for a third round of osseous surgery. She had contacted our office after seeing a TV report on the LPT procedure.

The patient had a medical history of hernia, gall bladder, cervical cancer surgery with estrogen replacement therapy of 2 mg per day, and an allergy to penicillin. She also reported smoking one-half pack of cigarettes per day. Dental exam and history revealed a considerable amount of dental treatment bilaterally on the posterior teeth, with crowns and silver amalgam fillings. The condition of the patient's soft tissue showed evidence of resective osseous surgery, with significant gingival recession and root exposure. The tough, fibrous appearance was consistent with chronic smoking. There appeared to be considerable impact trauma against the maxillary and mandibular crowns in the posterior segments. Full-mouth radiographs demonstrated generalized vertical bony defects limited to the posterior segments. Periodontal charting indicated 7- to 10-mm pocket depths in the posterior teeth. Only 15 sites probed normal, and 19 sites probed 8 mm or greater. MPD at baseline was 5.75 mm. The diagnosis of recurrent type IV or advanced periodontal disease and primary occlusal trauma was recorded.

Left side quadrants were treated with LPT in December 1997, along

with a maxillary frenectomy for aesthetic considerations. Right quadrants were treated 8 days later.

The Dentica (Xintec) pulsed Nd:YAG laser was used for this patient. An improvement over the dLase 300 was the availability of five pulse durations. For this case troughing around the tooth was done with a "short pulse" having duration of 150 microseconds. Pulse energy was set to 160 mJ and repetition rate was 30 Hz, giving an average power of 4.8 watts. The parameters for the coagulating or "long pulse" used to finish the procedure were 500-microsecond duration, 215 mJ, 20 Hz giving an average power of 4.3 watts. (Please note: 4.8 watts average power is recommended for only the most experienced laser user.†)

Another advantage of this laser system was the readout of total energy delivered during the procedure. This value is essential in determining the light dose.‡ To compute light dose the total energy delivered is divided by the sum of the depths of all pockets, which, in this case, was 15.2 J/mm pocket depth.

The patient tolerated the procedure well with no complications or adverse effects. Immediately post-op a periodontal dressing to protect the gum tissues from the direct effects of smoke toxicity and irritation was placed in each quadrant, to be removed 1 week postoperatively. Condition of the periodontal tissues 1 week post-op was remarkable in the appearance of healing in spite of the fact that the patient was a smoker. No evidence of further recession was noted.

Periodontal maintenance by the patient was dutiful and consistent at 3-month intervals. A follow-up exam was done at 8 months post-treatment. Heavy tea and smoke stains were present, along with light calculus and a healthy-appearing gingiva.

Probing depths charted 8 months post-treatment provide a quantitative index of the efficacy of LPT. The 19 pockets ≥ 8 mm have been reduced by an average of 4.4 mm, from an MPD of 8.3 mm pretreatment to an MPD of 3.9 mm. Overall, pockets ≥ 4 mm (153 sites or 91% of all sites) have been reduced by an average of 3.1 mm (Table). Much of the improvement is accounted for by a length of upper and lower anterior tissue surrounding teeth Nos. 6

through 12 and 20 through 28 where the gingiva was pink, tight, nonhemorrhagic, and healthy-appearing, and probing depths were predominantly 2 mm. Examples of before and after probe depths for teeth Nos. 18, 19, and 20 are shown at the bottom of Figure 3.

A comparison of the pre-treatment x-ray of the bone surrounding teeth Nos. 18 and 19 with the x-ray obtained 17 months post-treatment shows strong evidence of increased bone density. The density profiles at the bottom of Figure 3 demonstrate this clearly. Notice that the interproximal areas of alveolar bone between teeth Nos. 19 and 20 and 18 and 19, and the furcation of tooth No. 19, are radiolucent before treatment, indicative of severe inflammation. By 17 months post-treatment these areas had opacified.

CASE NO. 3

A 40-year-old white male presented on September 2, 1997, for a full-mouth x-ray exam and second opinion consultation on treatment planning. His primary concern was the scheduled removal of the upper left maxillary canine (tooth No. 11) scheduled for the following week. His previous dentist had said that the tooth was hopelessly pathologic and could not be saved. The patient's medical history revealed nothing remarkable. His dental history showed a considerable amount of dental treatment performed bilaterally on the posterior teeth, with crowns, silver amalgam fillings, and a missing tooth replaced with a bridge. Full-mouth radiographs demonstrated three teeth with root canal therapy, one of which was failing, and generalized vertical bony defects throughout his mouth.

The radiograph of tooth No. 11 indicated a deep vertical and three-wall defect on the mesial-lingual to distal-lingual aspect, extending from the crestal bone at the CEJ down the coronal aspect to the apical border of the middle one third of the root (Figure 4). Clinical examination revealed tooth No. 11 to have a class III mobility (apically mobile) and an extremely hard fremitus. The patient reported that palpation of any area around the tooth was tender to very painful.

One week later periodontal charting following local anesthesia demonstrated bony defects and periodontal pocketing measuring up to 19 mm. The

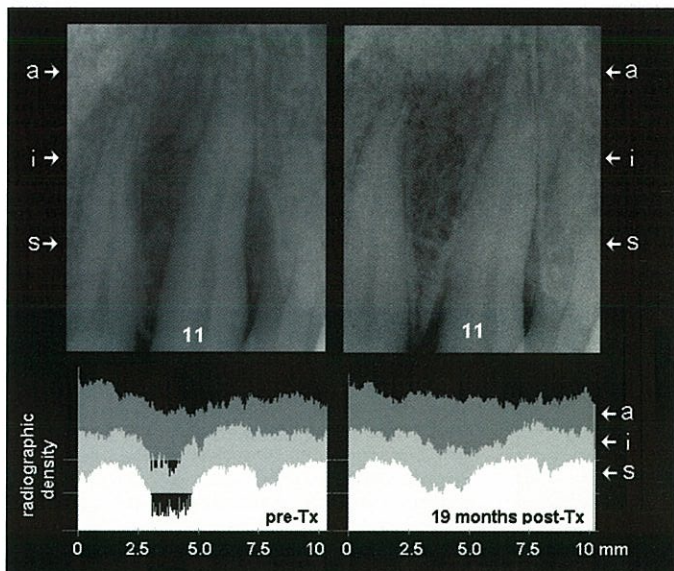


Figure 4. Case 3. Top: Radiograph showing close-up of tooth No. 11 before treatment (left) and 19 months post-treatment. Teeth were aligned and gray scales balanced using Emago software. Three areas of density profiles are indicated with (s), (i), and (a). Bottom: Before and after profiles are plotted for sections through superficial (s), intermediate (i), and apical (a) aspects of the alveolar processes mesial and distal to tooth No. 11.

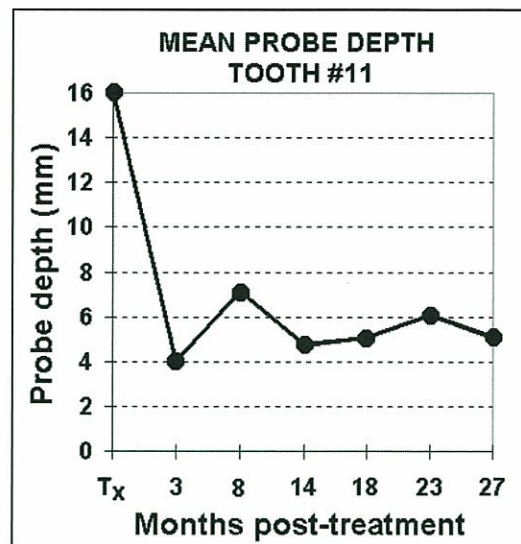


Figure 5. Case 3. Mean probe depths, tooth No. 11.

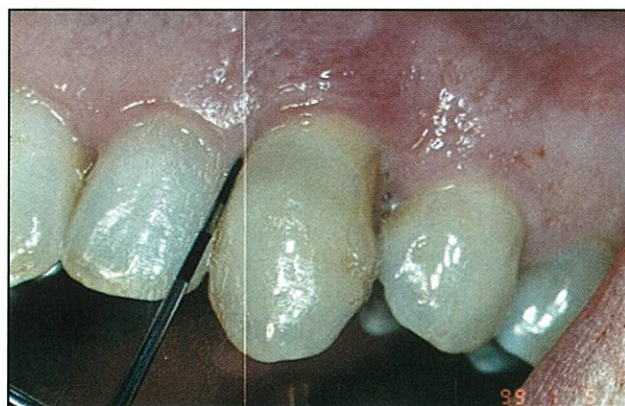


Figure 6. A 28-month clinical follow up shows a 3-mm probing depth of the mesial-facial demonstrating clinical success over time.

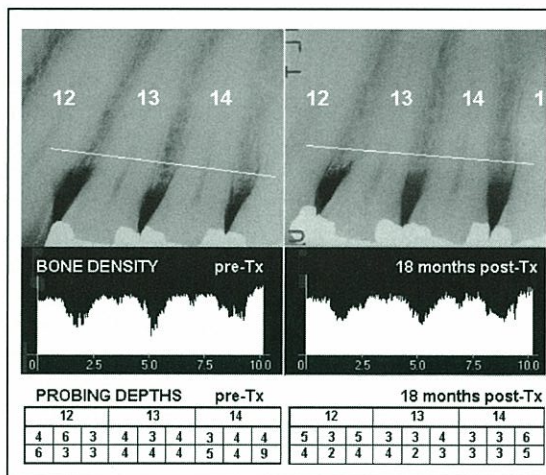


Figure 7. Case 4. Top: Radiograph showing close-up of teeth Nos. 12, 13, and 14 before treatment (left) and 18-month post-treatment. Teeth were aligned and gray scales balanced using Emago software. The straight line drawn across the images indicates the location of the radiographic density profiles. Middle: Density profiles of line drawn on images. Bottom: Probing depths for teeth Nos. 12, 13, and 14 prior to treatment and at the 18-month follow-up exam.

probing depths of 162 sites around 27 teeth showed a MPD of 5.4 mm, with 20 pockets \geq 8 mm. Tooth No. 11 presented a serious problem, with facial probe depths of 18, 9, and 16 mm and lingual depths of 19, 17, and 17 mm (Figures 4 and 5).

The Dentica laser was used on this patient. The "short pulse" for troughing had 160-microsecond duration and the "long pulse" for finishing was 500 microseconds long. For the entire procedure the laser was set to 160 mJ, 30 Hz for an average power of 4.8 watts. Left quadrants were treated first, and right quadrants treated 1 week later. The light dose was 16.3 J/mm pocket depth.

Two weeks after LPT had been performed on all four quadrants, fremitus was addressed on tooth No. 11 with occlusal and incisal stabilization. At 1-month postoperative follow-up, evaluation showed tooth No. 11 was again in

fremitus and was addressed. The tooth had stabilized in apical motion but was still moderately class II mobile. Light periodontal probing indicated a 9-mm periodontal pocket on the distal-facial and distal-lingual. Laser curettage was performed without anesthesia.

At 3 months postoperative, a periodontal maintenance visit including fine scaling and root planing was performed, along with laser curettage restricted to specific problem sites. The fremitus on tooth No. 11 was assessed and was continuing to improve with a class I fremitus. It was noted that the patient was maintaining very good oral hygiene.

Six months postoperatively, after a second periodontal maintenance visit, LPT was performed a third time on tooth No. 11 only. On the distal-facial and distal-lingual of tooth No. 11, pockets were 7 and 8 mm, respectively. All other pockets on this tooth were 3 mm

or less. There was no fremitus, and the tooth was stable.

Probing depths around tooth No. 11 were monitored at approximate 4-month intervals. The response of tooth No. 11 to treatment was both immediate and exceptional. Figure 5 shows average pocket depths for six sites around tooth No. 11. The significant pocket reduction observed at 3 months regressed slightly at 6 months, and reached a final value by 27 months.

Probe depths at 14 and 27 months showed great improvement (Table). The pockets \geq 8 mm were reduced, on average, by over 7 mm. The \geq 4-mm pockets showed acceptable improvement of -2.4 mm and -2.3 mm at 14 and 27 months, respectively.

At 14 months post-treatment radiography demonstrated an obvious change in the interproximal regions surrounding tooth No. 11 (Figure 5),

Table. Mean Probe Depth Changes

Mean Probe Depth Changes (mm) Following Laser Periodontal Therapy								Clinical Trials
CASE	1	2	3	4	5	20	28	
Months Post-Tx	20	8	14	27	5	20	28	
N =	134	168	162	162	168	168	162	
≥ 4 mm MPDC	-	-	-	-	-	-	-	-1.7 mm
N =	81	153	123	123	99	99	95	UTHSC
≥ 6 mm MPDC	2.7	3.6	4.2	4.3	0.9	2.9	1.8	
N =	24	115	50	50	34	34	31	
≥ 7 mm MPDC	3.5	3.9	6.4	6.5	3.4	4.1	2.6	-4.2 mm
N =	12	105	24	24	11	11	10	UNMC
≥ 8 mm MPDC	4.1	4.4	7.1	7.2	3.5	4.4	3.1	
N =	7	19	20	20	8	8	7	

Mean probe depth changes (MPDC) in millimeters for the four cases presented. Mean probe depth is computed as the arithmetic mean of all probing depths by quadrant or patient. MPDCs represent the mean of the differences from the baseline to the follow-up interval, stratified for pocket depth as indicated. The Clinical Trials column shows published data for comparison: the University of Texas Health Science Center (UTHSC) laser Group MPDC for pockets > 4 mm at 6 months, and the University of Nebraska Medical Center (UNMC) MPDCs following flap with osseous resection at 10 weeks post-treatment.

the distal pocket had retracted, the entire alveolar process between teeth Nos. 10 and 11 showed significant increase in density, and what appeared to be new bony structures were evident in the superficial portion. This change in density is represented graphically by the density profiles at the bottom of Figure 5. At 28 months post-treatment, clinical success was noted by a 3-mm probing depth (Figure 6).

CASE NO. 4

A 54-year-old white male first presented in March, 1998, having seen a local TV news report on LPT. The patient had previous conventional gum surgery and wanted to see if the laser method might have some advantage.

The patient's medical history was unremarkable. Dental history was notable for osseous resective surgery performed 5 years previous, with the need to repeat the removal of more bone and soft tissue. The patient had numerous crowns and silver amalgam restorations limited to the upper and lower posterior teeth, with one root canal therapy completed in tooth No. 2. The soft tissue did not exhibit signs of periodontal disease except for the gingival recession and root surface exposure associated with the previous subtraction blade surgery. Heavy occlusal impact trauma was noted on the posterior teeth and restorations. The patient had pockets 5, 6, 7, and 8 mm limited to the posterior teeth. Twenty-eight teeth (168 sites) had an MPD of 4.22 mm.

Right quadrants were treated on April 21, 1998, and left quadrants were

treated 1 week later. Previous surgery had rendered the gingiva tough and fibrous. A higher repetition rate and lower pulse energy than usual was used (60 Hz, 50 mJ), producing a "hot glass" effect to accomplish the task of quickly troughing each tooth. Because treatment time remained about the same, and the average power was 3 watts, the light dose was only 12.4 J/mm pocket depth. Seven-day postoperative evaluations indicated the areas were healing well (Figure 7).

Probe depths charted at 5 and 20 months postoperative showed promising results. Pockets ≥ 8 mm were reduced by 3.5 and 4.4 mm, respectively, and intermediate pockets showed moderate improvement (Table). However, by 28 months many previously normal 3- to 5-mm pockets probed deeper than baseline, so the MPDC showed only marginal improvement relative to pretreatment.

Radiographic findings showed evidence of interproximal bone fill and what seemed to be new bony structures interproximal to teeth Nos. 14 and 15 (Figure 7). Notice that the densities in the region of the roots and the root canals were balanced with gamma correction to yield approximate equal values.

DISCUSSION

"Typical" as used here applies to clinical judgment and is not meant in a statistical sense. More detailed, quantitative comparative analyses of the efficacy of LPT with a larger sample size are in preparation. Although presented as unique examples, these cases can be

compared with published data for a better understanding of how these patients have fared relative to alternative treatments.

Neil and Mellonig⁸ at the University of Texas Health Science Center, San Antonio, (UTHSC) reported on 10 patients treated in a controlled study where pulsed Nd:YAG laser (ADT PulseMaster) was used in a protocol of oral hygiene, scaling, root planing, and laser curettage, a technique similar to LPT. Pulse duration was constant at 100 microseconds, energy per pulse was 80 mJ, repetition rate was 25 Hz, and average power was 2 watts. A dosimetry table defined light dose based on pocket depth, and ranged from 6.6 to 10 J/mm pocket depth. Recall that the light doses for cases 2, 3, and 4 were 15.2, 16.3, and 12.4 J/mm pocket depth, respectively. The UTHSC laser group MPDC for pockets ≥ 4 mm at 6 months was -1.7 mm, shown for comparison in the far right column of the Table.

It is not surprising that case 1 had a similar clinical outcome as obtained in the UTHSC study, with a MPDC for pockets ≥ 4 mm of -1.6 mm. Case 1 was typical of our early patients who were treated with a laser similar to the UTHSC laser at 3 watts.

Because we have not been running clinical trials, but running a clinical practice, we have had the luxury of adjusting parameters and modifying our protocol as we go along. When we changed from the dLase 300 to the Dentica Laser, the addition of the long pulse width improved intraoperative

hemostasis and shortened the overall time in the chair. The energy readout has allowed us to keep track of light dose and to compare dosimetry with clinical outcomes. From this we have developed procedural-based dosimetries. We have also added modifications to the overall treatment program. Over the years, LPT has evolved to the proper application of laser technology plus a medically sound approach to wound management. Consequently, case 2 represents what is now, in our clinical judgment, considered to be "typical."

Results such as those for cases 2 and 3 demonstrate pocket depth reductions that are comparable with currently accepted surgical techniques. Kaldahl et al⁹ conducted NIH-supported clinical trials with 82 patients (2,090 teeth) at the University of Nebraska Medical Center (UNMC) to evaluate different modalities of treatment for periodontitis. They measured probing depths and compared efficacy (MPDC) among four procedures: coronal scaling, root planing, modified Widman, and flap with osseous resection. The flap with the osseous resection surgical procedure was the most successful in MPD reductions. For pockets with depths ≥ 7 mm, the study reported MPDC of -4.18 mm at 10 weeks (Table) and -3.68 mm at 1 year. This is comparable with case 2 (≥ 7 mm MPDC of -3.9 mm at 8 months). In this case, the outcome of LPT therapy is comparable with the "statistically typical" outcome of the most efficacious procedure in the UNMC study. Comparison of case 3 with the UNMC study illustrates why we judge this outcome to be exceptional, with a ≥ 7 mm MPDC of -6.5 mm.

The changes we have observed in bone density are very similar to those reported by Dubrez et al.¹⁰ Comparison of our preliminary radiographic findings with this study is useful because the quantitative radiographic analyses are identical in concept to the density profiles generated by Emago.*

In the Dubrez et al¹⁰ study, interproximal sites in patients who demonstrated bone loss in association with ≥ 5 -mm pocket depths were evaluated. Treatment consisted of coronal scaling, root planing, topical antibiotics, and rigidly maintained oral hygiene. They observed improved bone density at 1 year. A quantitative comparison of bone density changes seen in that study versus what we observe in our patients is beyond the scope of these case reports. However, it is not unexpected that if we see clinically a general improvement in the health of the surrounding tissues, we will also see a subsequent increase in the radiographic density of alveolar bone.♦

Acknowledgment

The authors wish to thank David M. Harris, PhD, Bio-Medical Consultants, Inc, Castro Valley, Calif, for data processing and graphic presentations and Leigh Colby, DDS, for the pocket-depth spreadsheet.

References

1. Yukna RA, Bowers GM, Lawrence JJ, et al. A clinical study of healing in humans following the excisional new attachment procedure. *J Periodontol.* 1976;47:696-700.
2. Gregg RH, McCarthy DK. Laser ENAP for periodontal bone regeneration. *Dent Today.* 1998;17:88-91.
3. Gregg RH, McCarthy DK. Laser ENAP for periodontal ligament (PDL) regeneration. *Dent Today.* 1998; 17:86-89.
4. Gold SI, Vilardi MA. Pulsed laser beam effects on gingiva. *J Clin Periodontol.* 1994;21:391-396.

5. Midda M, Renton-Harper P. Lasers in dentistry. *Br Dent J.* 1991;170:343-346.
6. Moritz A, Schoop U, Goharkhay K, et al. The bactericidal effect of Nd:YAG, Ho:YAG and Er:YAG laser irradiation in the root canal: an in vitro comparison. *J Clin Laser Med Surg.* 1999;17:161-164
7. Whitters CJ, TW MacFarlane, D McKenzie, et al. The bactericidal activity of pulsed-Nd:YAG laser radiation in vitro. *Lasers Med Sci.* 1994;9:297-303.
8. Neill ME, Mellonig JT. Clinical efficacy of the Nd:YAG laser for combination periodontitis therapy. *Pract Periodontics Aesthet Dent.* 1997;9(6 suppl):1-5.
9. Kaldahl WB, Kalkwarf KL, Patil KD, et al. Evaluation of four modalities of periodontal therapy: mean probing depth, probing attachment level, and recession changes. *J Periodontol.* 1988;59:783-793.
10. Dubrez B, Graf JM, Vuagnat P, et al. Increase of interproximal bone density after subgingival instrumentation: a quantitative radiographic study. *J Periodontol.* 1990;61:725-731.

Notes

* Analog x-ray films were digitized and analyzed with Emago (Advanced Medical Devices, Richardson, TX) and Photoshop software (Adobe Systems Inc). In Emago the pretreatment reference image and the post-treatment images were balanced for differences in exposure and film processing characteristics with gamma correction. Gamma correction is a computerized algorithm that modifies the gray level distribution of an image using the gray level distribution of another image as a reference. The software provides means of quantitative analysis of corrected radiographic densities through the use of density profiles. The density profiles shown in Figures 2, 3, 5, and 6 represent a plot of the gray value of each pixel along a line through the x-ray that is selected by the user. Each gray value represents the relative radiographic density at that point in arbitrary units. Emago geometric reconstruction is a useful alternative to obtaining before and after x-rays with identical projection geometry. In subtraction radiography this is provided by consistently using individual bite blocks or other aiming techniques (refs). Emago Geometric Reconstruction produces a pair of images with identical image formation geometry by mapping the information contained in one image onto the projection plane of a reference image. After projection corrections and density analysis, the two images were combined to produce one side-by-side image that was filtered in PhotoShop (contrast and sharpness) to enhance visualization of bony features.

† CAUTION. Laser dosimetry described in this article is NOT recommended unless the practitioner is well-trained and experienced. Exceeding the laser parameters described for these cases may lead to prolonged healing and other complications.

‡ Light dose (Joules per mm pocket depth) is similar to drug dose (mg per kg body weight) in that light dose defines the concentration of laser energy at the treatment site in a similar manner as drug dose defines the concentration of a drug in the tissues. Light dose is a very useful parameter in as much as certain clinical outcomes of laser surgery (eg, adverse effects) are dose dependent.

Dr. Gregg has been using lasers clinically since August, 1990, including CO₂, Pulsed Nd:YAG, surgical and photopolymerization Argon, and Er:YAG. He has given lectures nationally and internationally on the subject of clinical laser applications, and has conducted seminars for the UCLA Department of Continuing Education. In addition to authoring several peer-reviewed articles on the clinical applications of pulsed Nd:YAG for endodontic and periodontal uses, he is an author of the Laser Curriculum Guidelines, versions 1 and 2. Dr. Gregg has obtained his Mastership and Educator's Certification in the Academy of Laser Dentistry. He maintains a private practice and may be contacted at (562) 860-6587 or rgregg@millenniumdental.com.

Disclosure: Dr. Gregg is a codeveloper of the FDA-cleared PerioLase pulsed Nd:YAG laser, and is a founder of Millennium Dental Technologies, Inc. He is a codeveloper and patent holder of the Laser ENAP periodontal technique.

Dr. McCarthy has been using lasers clinically since November, 1989, including CO₂, Pulsed Nd:YAG, surgical and photopolymerization Argon, and Er:YAG. He has given lectures nationally and internationally on the subject of clinical laser applications, and has conducted seminars for the UCLA Department of Continuing Education. In addition to authoring several peer-reviewed articles on the clinical applications of pulsed Nd:YAG for periodontal uses, he is an author of the Laser Curriculum Guidelines, versions 1 and 2. He has obtained his Mastership and Educator's Certification in the Academy of Laser Dentistry. He divides his time between practicing dentistry and teaching laser periodontal therapy and may be contacted at (562) 860-2908 or dmccarthy@millenniumdental.com.

Disclosure: Dr. McCarthy is a codeveloper of the FDA-cleared PerioLase pulsed Nd:YAG laser, and is a founder of Millennium Dental Technologies, Inc. He is a codeveloper and patent holder of the Laser ENAP periodontal technique.

Millennium Dental Technologies, Inc., distributor of the PerioLase, does not currently possess FDA clearance for some or all of the claims made in these articles.