

# Periodontal Bone Regeneration with an Nd:YAG Laser and LANAP® Protocol

**Raymond A. Yukna, DMD, MS**

**Professor**

**Advanced Periodontal Therapies**

**University of Colorado**

**School of Dental Medicine**

**Aurora, CO, USA**



Osteology Meeting  
Cannes, France  
Poster # 331  
April 2011

LANAP® protocol



## Abstract

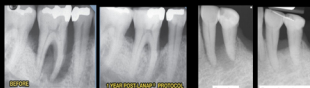
**Objective:** The purpose of this presentation is to illustrate the radiographic and histologic bone regeneration seen following the Laser-Assisted New Attachment Procedure™ (LANAP®) surgery using an Nd:YAG laser (PerioLase® MVP™) (Millennium Dental Technologies, Inc, Cerritos, CA) in humans. LANAP® is a single session surgical treatment.

**Methods:** Pre-treatment and post-treatment dental radiographs of patients treated for chronic periodontitis or peri-implantitis with the LANAP® Protocol (Laser-Assisted New Attachment Procedure™) surgery are presented.

**Results:** Consistent increase in bone support for both natural teeth (infrabony defects and furcations) and dental implants with peri-implantitis has been seen with the LANAP® surgical protocol. The cases shown illustrate various examples of periodontal and peri-implant bone regeneration. Human histology reinforces the radiographic findings.

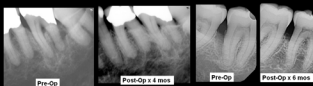
**Conclusions:** The LANAP® Protocol (Laser-Assisted New Attachment Procedure™) surgery using an Nd:YAG laser shows appreciable potential for periodontal and peri-implant bone regeneration.

## Periodontitis



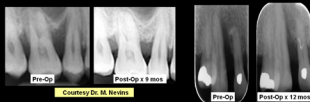
Courtesy Dr. R. Gregg

Courtesy Dr. P. Rubelban



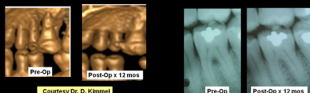
Courtesy Dr. N. Lehman

Courtesy Dr. L. Flakbeiner



Courtesy Dr. M. Nevins

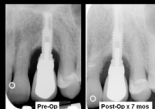Dr. R. Yukna



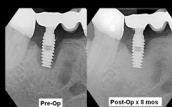Courtesy Dr. D. Kimmel

Courtesy Dr. K. Rathbun

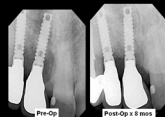## Peri-implantitis



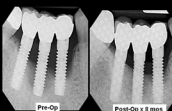
Courtesy Dr. K. Blodgett



Courtesy Dr. J. Fountier



Courtesy Dr. J. Fountier



Courtesy Dr. B. Seamos

## Human Histology

**Key:** N = notch in calculus; B = new bone  
C = new cementum; OC = old cementum;  
JE = junctional epithelium

