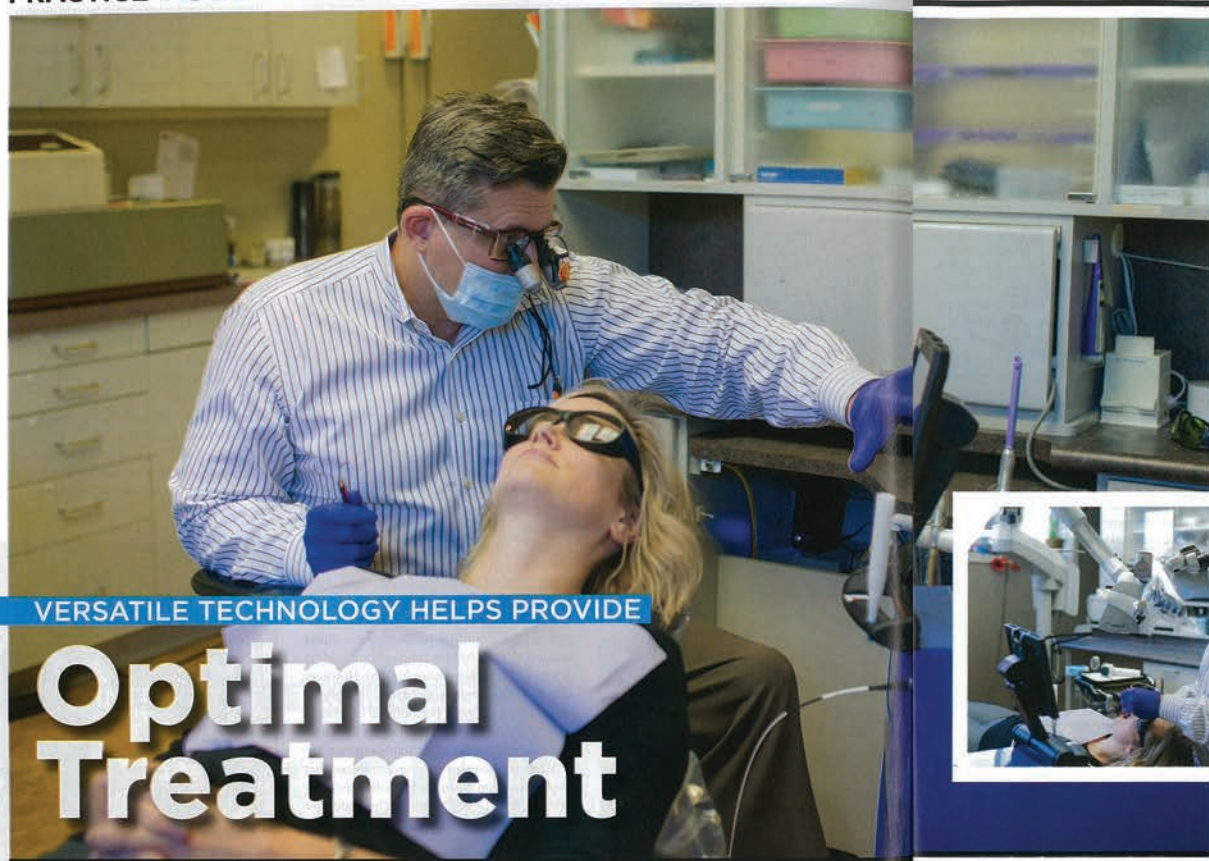

VERSATILE TECHNOLOGY HELPS PROVIDE

Optimal Treatment

Dentist uses PerioLase® MVP-7™ for wide variety of procedures

Dan Boyko, DMD, spent much of the first decade-plus of his career on the road in northern Canada. Boyko's father, Jerry, operated a practice in Sainte Rose du Lac, Manitoba, and had government contracts with nearby aboriginal reserves. Each week, the younger Boyko would make the 3-hour drive from his home

in Winnipeg, Manitoba, to work in his father's practice on Monday, then drive another hour and a half to visit two reserves, then finally return home to Winnipeg on Wednesday night. "The experience was fantastic," Boyko says. "Decay was present on every tooth for some patients. The government contracts allowed

us to select optimal treatment plans rather than, in some cases, simply extracting teeth. This experience provided a great avenue to build up my skills in endodontics, oral surgery, crown- and bridgework, and more."

In 2002, Boyko joined a practice back in Winnipeg, and by early 2005, the other three

dentists had retired, leaving him to take over the entire practice. Since taking the helm, he has built it with an emphasis on a philosophy that he attributes to educator Frank Spear, DDS, MSD.

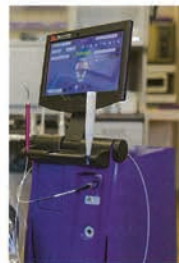
"If a tooth is there, we want to keep it there for as long as possible before it leaves the mouth," Boyko says. "We want to preserve what Mother Nature gave us."

Boyko's experience working with so many severely compromised dentitions early in his career helped him develop the skills necessary to subscribe to that philosophy, and he supplements those skills with technology. He purchased his first diode laser in the early 2000s and added a chairside CAD/CAM system soon after. He mills approximately 40% of his indirect restorations in the office.

One of Boyko's favorite pieces of technology is the PerioLase® MVP-7™ for the LANAP® protocol from Millennium Dental Technologies.

At first, Boyko used the PerioLase only for "value-added" procedures such as dentin etching and endodontic sterilization. His first patient for the LANAP periodontitis treatment protocol was his mother, Patricia.

"She had a 13-mm pocket on a lower molar and asked if it would hurt afterward. I had been assured that it would not, but I still was concerned," Boyko says. "There were no problems, and she went from 13 mm to 5 mm a year later without needing to heal from a traditional flap and deal with the post-operative pain that would have been involved with that procedure."



Boyko previously performed traditional flap surgeries frequently, and he jokes that patients usually did not want to see him the next day.

"What is great about the LANAP protocol is that it literally regenerates bone using only the PerioLase MVP-7 and the body's natural healing process. It removes the inner lining where the bacteria live and destroys them without harming healthy tissue," he says. "Getting the same results using traditional methods is difficult. We do not cut a flap, so there is minimal recession afterward. In the anterior region with a high smile line, that can

be very important. Also, the recovery period is basically only 24 hours. I have performed approximately 90 full-mouth cases, and the patients have almost no discomfort."



Boyko also uses the PerioLase MVP-7 for gingivectomies, gingivoplasties, frenectomies, and other soft-tissue procedures. Pulp-capping, caries removal, opening up a mesial-lingual calcified canal, welding a cracked tooth, and stimulating the bone before implant placement are just a few of the many other applications.

The biostimulation feature can be used in a number of situations other than implant placement.

"It works immediately," he says. "We had one patient whose mouth could not even open due to swelling from a third-molar infection, and biostimulation with the laser allowed the patient to open enough for us to look in there within 10 minutes. We also performed biostimulation on a patient with Bell's palsy who reported that we took away all of her pain and restored almost all of her feeling within 2 months."

Another patient presented with severe peri-implantitis affecting two lower implants that had been placed by a different dentist for a complete lower denture.

"They were bleeding and infected with a bit of bone loss," Boyko says. "After laser treatment, the patient could not believe how good the gums looked 1 month later."

Boyko recently purchased a second PerioLase MVP-7 so his two associates could have one of their own to share.

"I wanted one all to myself because I use it somehow, in some way, on every patient I treat," he says. "I refer to this laser as 'hope for the hopeless tooth.' I think it will eventually become the standard of care."