

## PATIENT HISTORY

A 63-year-old female returning patient returned to our office on 12/1/17 for a routine exam. In 2012, our office had placed an implant in the site of #30. The patient reported she was in excellent health, without medications or conditions that would complicate healing. Upon clinical examination, the patient was asymptomatic; gingival tissue was normal, no bleeding on probing, purulence, or mobility. Upon examination of routine radiographs, peri-implantitis was noted on both the mesial and distal of #30. A lesser degree of bone loss was noted around implant site #29. Despite the visual loss of bone in the radiograph, the implant did not have outward signs of infection and the patient was not in pain.

## TREATMENT APPROACH

The patient was recommended the LAPIP protocol for peri-implantitis, in part due to the unpredictability of results associated with other treatment methods. Given the minimally invasive nature of the LAPIP protocol, selecting this treatment option as a first-line approach retains the gingival margin and preserves other regenerative options if the treatment is not successful. The patient was informed of treatment options and selected to move forward with the LAPIP protocol. The patient was scheduled for treatment on 3/7/18. Treatment was according to the LAPIP protocol including regular maintenance visits.

## RESULTS

The patient was very compliant with home care following LAPIP treatment. One year post-operative follow up examination on 2/27/19 showed no change in the gingival margin and no recession. Radiographs showed noticeable bone regeneration around the implant placed in #30 and the implant continues to be stable. Bone regeneration around #29 corresponded to depth of visual defect noted pre-treatment.



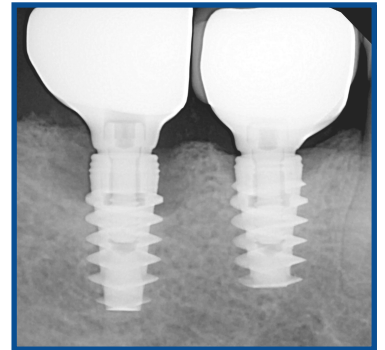
### ABOUT THE AUTHOR: JONATHAN TSANG, DMD

Dr. Jonathan Tsang attended the University of British Columbia where he studied mathematics before heading to Philadelphia to study at Temple University School of Dentistry. Upon graduating, Dr. Tsang returned to his hometown of Abbotsford to open his dental practice.

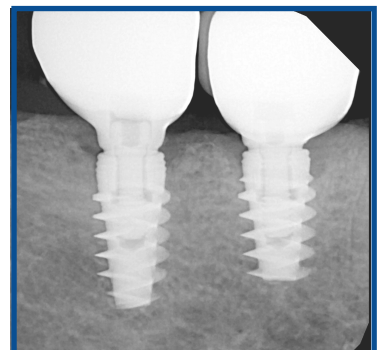
Dr. Tsang is Diplomate of the American Board of Oral Implantology/Implant Dentistry (ABOI/ID), a designation shared by

fewer than 50 dentists in all of Canada. Certification by the ABOI/ID attests to the fact that Dr. Tsang has demonstrated knowledge, ability, and proficiency in implant dentistry through a rigorous examination process. He is a Fellow of the American Academy of Implant Dentistry and an active member of the Academy of General Dentistry, the Canadian Dental Association, and the British Columbia Dental Association.

Pre-Op



1 Year Post-Op



SEE MORE  
LAPIP RESULTS

SCAN  
QR CODE

