

Courtesy of Jessica Allen, DMD, MSD

LAPIP® Periodontist since 2018 | Fort Collins, CO
Periodontal Residency from Virginia Commonwealth University

PATIENT HISTORY

A patient was referred to my office in December 2019 for an infection with dental implant #19. The patient is a retired physician, age 77, with a history of high blood pressure that is controlled with medication. Probing depths around #19 were 10, 9, 9 | 7, 6, 6 with suppuration on the mesial buccal and mesial lingual with 1 mm recession on the straight buccal and lingual. Patient requested treatment to manage and maintain his dental implant with the least invasive approach possible. Due to the severity of bone loss on implant #19, I explained to patient there was a guarded prognosis of the implant even with treatment.

After the initial examination, the patient was diagnosed with Localized Stage 3 periodontitis, grade B; generalized secondary occlusal trauma; and peri-implantitis #19. Periodontal therapy was recommended to manage his overall periodontal condition with LAPIP treatment for implant #19. An alternative was to extract the dental implant at 19. Patient was not agreeable to extracting the implant and wanted to try and do what he could to save it.

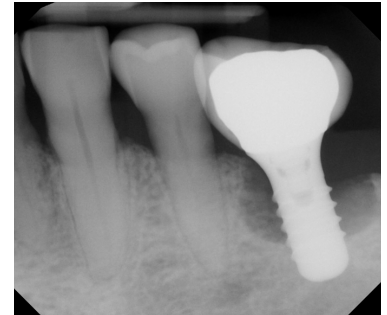
TREATMENT APPROACH

The patient chose the LAPIP protocol with the goal of stabilizing the implant, rather than removing. Upon assessment of the severity of bone loss and potential for increased trauma during removal of the cement-retained crown, LAPIP treatment was done with the crown intact in December 2019. Occlusal adjustment was performed on the implant at initial treatment and ongoing during maintenance visits per the LAPIP protocol. The patient was placed in an occlusal guard as his final therapy.

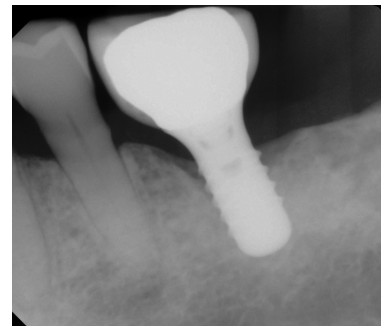
RESULTS

Despite office closures affecting many during the COVID-19 pandemic, the patient kept all scheduled post-operative visits and periodontal maintenance visits, all while maintaining good oral home care.

Radiographs taken in November 2020 showed clear bone fill with probing depths of 4, 2, 3 | 3, 2, 4. No bleeding or suppuration was noted and the patient indicated he was extremely happy with the results and the minimal pain/discomfort he had throughout the whole treatment process. Patient continues to be maintained in the office every 3 months. Probing depth reduction and bone health continues to persist.



Pre-Op
10, 9, 9 | 7, 6, 6



11 Month Post-Op
4, 2, 3 | 3, 2, 4



ABOUT THE AUTHOR: JESSICA ALLEN, DMD, MSD

Dr. Jessica Allen graduated magna cum laude and was inducted into Omicron Kappa Upsilon, a national dental honor society. She received her certificate in Periodontics and Master's of Dental Sciences from Virginia Commonwealth University where she served as chief resident and clinical instructor in the pre-doctoral clinic.

Dr. Allen has also achieved the highest certification in her specialty with board certification in Periodontology and Dental Implant Surgery. She currently holds office as President of Larimer County Dental Society, member of Colorado Dental Association's Council of Component leadership committee, Co-Director for Mountain West Dental Forum, Co-Director of Rocky Mountain Dental Hygiene Study Club and Spear Dental Study Club Specialty advisor.

