

**Courtesy of Yetta McCullom, DDS, MS**LANAP® periodontist since 2008, Chicago, IL  
IALD Certified Instructor**PATIENT HISTORY**

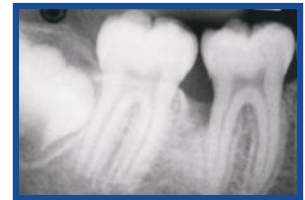
A 16-year-old African American female presented on 8/27/09 for a periodontal examination. She had seen the orthodontist for correction of her malocclusion. His exam showed pocketing on the mesial of the lower first molars. Teeth were not mobile and there was no recession. A full set of radiographs was taken confirming radiolucent defects on #19 and #30. A diagnosis of localized rapidly progressive periodontitis was given. Treatment recommendation was the LANAP® protocol.

**TREATMENT APPROACH**

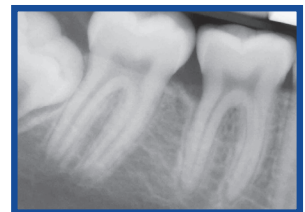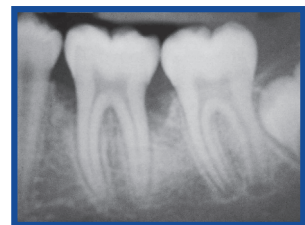
On 9/18/09, the LANAP® protocol was completed. Number 19 and #30 were adjusted out of occlusion. Follow up was done two weeks later with minor occlusal adjustments.

**RESULTS**

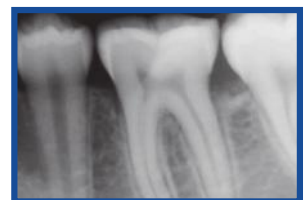The patient did not return until 4/29/2011 for follow-up. At that time, radiographs were taken showing evidence of bone regeneration. Periodontal charting was done one year post-LANAP® protocol showing significant improvement in pocket depths. Three years post-LANAP® protocol and one year post-ortho, her periodontal condition remains stable.



Pre-Op

12 months Post-LANAP®  
Protocol

Pre-Op

12 months Post-LANAP®  
Protocol**ABOUT THE AUTHOR: YETTA MCCULLOM, DDS, MS**

Dr. Yetta G. McCullom earned a Doctor of Dental Surgery degree from the Howard University College of Dentistry in 1985, then served as a general practice resident at the VA hospital in Washington D.C. She worked in private practice and as a clinical instructor in the Department of Periodontics at the Howard University for two years, then entered Northwestern University Dental School in Chicago where she received a Master of Science with a Certificate in Periodontics in 1990.

Dr. McCullom was trained in the LANAP® protocol for the treatment of periodontal disease in 2008 and was so impressed with the technique that she became an instructor for the Institute of Advanced Laser Dentistry. She is a member of the American Academy of Periodontology, the American Dental Association, Omicron Kappa Upsilon (Dental Honor Society), the Chicago Dental Society and the Midwest Society of Periodontics, the Illinois Society of Periodontists and the National Dental Association.